

## PHYSIOTHERAPY'S METHODS FOR NEURITIS N. FACIALIS

Milena Filipova, Daniela Popova, Angel Kantchev, Nadejda Borisova,  
Ekaterina Mitova and Leyla Kraydjikova

Department of Kinesitherapy, SWU Neofit Rilski, Blagoevgrad, Bulgaria

Preliminary scientific communication

### Abstract

The motor nerve is composed of sensory and secretory vegetative (salivary and lacrimal) fibers. Syndrome of peripheral paralysis of the facial nerve is paralyzed muscles of the entire front half in which it is granted and the person becomes asymmetrical. Start of damaged nerve flat increases on the forehead, eyes litis wider (lagophthalmos), interpretation corner leave the nasal labial fold. The patient cannot wrinkled forehead. Eye ball remains unobscured by turning up /Bell's symptom/. The reare no active movements in the affected facial half. The aim is to improve the trophic muscle. We use passive exercises, with help from kinesitherapist. Mimic movements are passive in normal volume. KT controls facial movements with a hand. If it is a necessary we can put a kinesiotapebar on the injured party, covering the muscles of the face, which is controlled by two branches of the n. facialis.

**Key words:** physical therapy, facial nerve, kinesiotaping

### Introduction:

#### Methods of physical therapy

Tasks- Objective: quickly removing mimic movement disorders

1. strengthen the blood and lymph circulation;
2. support the conductivity of nerve;
3. stimulation of the muscles innervated by the nerve;
4. prevention of pathologicalsynkinesis and contractures

#### Methodology

Performbased on MMT. The starting position is important. It is recommended occipital. Reduce tone and develop hypotrophy of the affected muscles, some of them extended. In the other side of the facial muscles increases the tone and shorted. In occipital leg occurs reduction of increased muscle tone. Gravity plays a role in muscle imbalances and damage n. facialis.

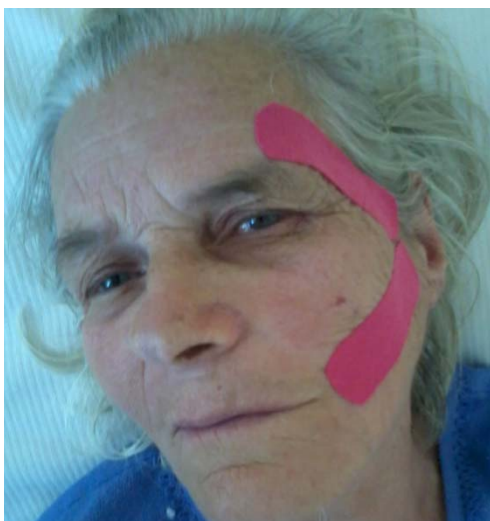

Figure 1. Kinesiotapyng in neuritis n. facialis

Massage collar preceded exercises (15 min). Kinesitherapy's treatment goes through three stages: I<sup>st</sup> stage: There are no active movements in the affected facial half. The aim is to improve the trophic muscle. We use passive exercises, with help from kinesitherapist.

Mimic movements are passive in normal volume. KT controls facial movements with a hand. If it is a necessary we can put a kinesiotapebar on the injured party, covering the muscles of the face, which is controlled by two branches of the n. facialis. II<sup>nd</sup> stage / appearance of active movements/. It aims to strengthen active movements. We have used passive exercises, isometric exercises, active exercises in the affected part is held.

III<sup>rd</sup> stage. The objective is to increase strength, mobility and coordination of the affected muscles. We have used an exercise against resistance.

### Results

We restudied 20 patients treated at the Neurological Department at the Blagoevgrad's hospital for a period of two years. Average age of the patients 45±8. Results of MMT:

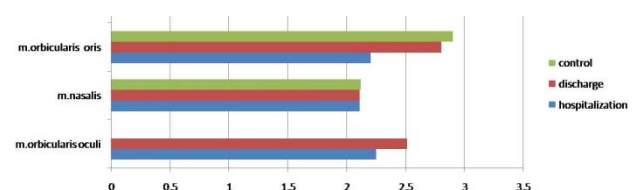


Fig. 3 Results of EMG

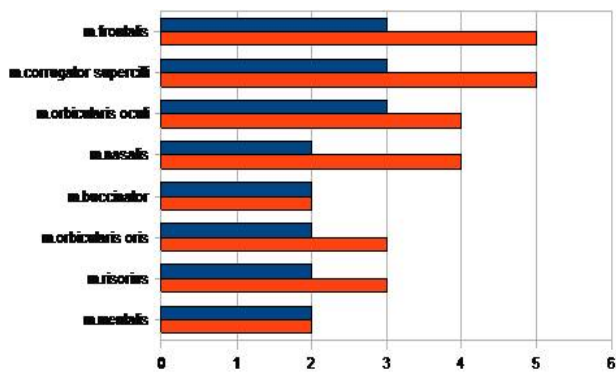


Figure 2 MMT of facial muscles (Results from EMG, EMG lat. Ms)

## Conclusion

Patients have achieved significant improvement. In our study is lagging behind in improving the motor functions of the muscles controlled by the lower branch of n. facialis /m. buccinator, m. orbicular isoris, m. risorius /. Muscle of the affected side is with are built tone, without the presence of pathological synkinesis.

Improved /decreased/ tone of hypertonic muscle of the undamaged side. The appearance of pathological synkinesis after the third week of acute onset is a prerequisite for the presence of contractures.

## References

- Банков, Ст., Слънчевт П. (1986). Ръководство по кинезитерапия. *Медицина и физкултура*, 210–216.
- Каранешев, Г., Милчева, Д., & Янчева, С. (1991). Методи на диагностика и изследване в лечебната физкултура. Sofia: HCA.
- Костадинов, А. (1979). Физикална терапия при неврит на лицеви нерв. *Медицина и физкултура*, 350.
- Иванова, Е., Рязкова, М., & Костадинов, Д. (1983). Рехабилитация на болни със след инсултни хемипарези. *Медицина и физкултура*, 440.
- Стаменова, П., & Миланов, Ив. (2012). Българска Неврология, *Алгоритми за диагностика и лечение на основни неврологични заболявания*, 12(2), 51-58; 64.
- Миланов, И. (2012), Неврология. *Медицина и физкултура*, 551.
- Петров, Р. (1998). *Неврология*. Sofia: Вѐда Словена-ЖГ.
- Попов, Н. (2008). *Въведение в КТ – основни средства и методи*. София: HCA прес.
- Попов, Н. (2003). *Клинична патокинезиологична диагностика*. София: HCA прес.
- Попов, Н. (2009). *Основи и средства на кинезитерапията*. София: HCA прес.
- Шотеков, П. (2002). *Учебник по Неврология*. София: Арсо.
- \* \* \* (2011). *Advanced concepts and corrective techniques of kinesio taping method (KT 2)*, Kinesio taping association international, Kinesio IP, LCC.

## FIZIOTERAPIJSKE METODE ZA NEURITIS N. FACIALIS

### Sažetak

*Motorički živac se sastoji od osjetilnih i sekretornih vegetativnih (za slinu i suze) vlakana. Sindrom periferne paralize živca lica paralizira mišići cijele prednje polovine lica za koju je zadužen i osoba postaje asimetrična. Početak oštećenih živčanih povećava se na čelo, šire očne regije (lagophthalmos), interpretacijski kut ostavlja nosnu labelu otvorenu. Pacijent ne može naborati čelo. Očna jabučica ostaje nepotamnjena okretanjem gore /Bellov Simptom/. Nema stražnjih aktivnih pokreta u zahvaćenoj polovini lica. Cilj je poboljšati trofički mišić. Koristimo pasivne vježbe, uz pomoć kinesitherapist. Pokreti lica (mimika) su pasivni u normalnom volumenu. KT kontrolira pokrete lica sa strane. Ako je potrebno možemo staviti traku kinesiotepe na oštećenika, koji pokriva mišiće lica, koji je pod kontrolom dvije grane n. facialis.*

**Ključne riječi:** fizikalna terapija, facijalni nerv, kinesiotaping

Received: July 14, 2015

Accepted: December 05, 2015

Correspondence to:

Mariela Filipova, PhD

SWU Neofit Rilski Blagoevgrad

Department of Kinesitherapy

66 IvanMihailovstr., 2700 Blagoevgrad, Bulgaria

E-mail mariela\_redm@yahoo.com